

Neurosyphilis and Clinical Variants

Neurosífilis e Variantes Clínicas

*Adriana Moro¹, Alisson Pittol Bresciani¹, Marcus Victor de Oliveira¹,
Pedro Henrique de Campos Albino¹, Melina Moré Bertotti², Ana Magda
Bruscato³, Luiz Paulo Queiroz⁴, Paulo Mattosinho Filho⁵*

ABSTRACT

Introduction. Neurosyphilis is an uncommon manifestation of central nervous system (CNS) infection caused by *Treponema pallidum*. **Cases.** We report three cases of neurosyphilis. Case 1 presented with ocular involvement: right optic atrophy and left optic neuritis; case 2 had a meningovascular form, with ischemic stroke; and case 3, a meningeal form, presented with headaches as the main complaint. **Discussion.** The cases reported had distinguished forms of neurosyphilis. Serologic diagnosis depends on the presence of antibodies: Veneral Disease Research Laboratory (VDRL) - not specific - and/or Fluorescent Treponemal Antibody Absorption (FTA-ABS) - specific. **Conclusion.** In the cases above cerebrospinal fluid FTA-ABS was a diagnostic clue for neurosyphilis even though unreactive serum VDRL was found.

Keywords. Syphilis, Central Nervous System, Neurosyphilis.

Citation. Moro A, Bresciani AP, Oliveira MV, Albino PHC, Bertotti MM, Bruscato AM, Queiroz LP, Mattosinho Filho P. Neurosyphilis and Clinical Variants.

RESUMO

Introdução. A neurosífilis é uma manifestação pouco frequente da infecção do sistema nervoso central (SNC) pelo *Treponema pallidum*. **Casos.** Nós relatamos três casos de neurosífilis. O caso 1 apresentava-se com envolvimento ocular: atrofia ótica à direita e neurite ótica à esquerda; o caso 2 uma forma meningovascular com Acidente Vascular Cerebral isquêmico; e o caso 3, uma forma meníngea, tinha como queixa principal cefaléias. **Discussão.** Os casos relatados apresentavam distintas formas de neurosífilis. O diagnóstico sorológico depende da presença de anticorpos: Veneral Disease Research Laboratory (VDRL) - não específico - e/ou Fluorescent Treponemal Antibody Absorption (FTA-ABS) - específico. **Conclusão.** Nos casos acima o FTA-ABS no líquido foi uma ferramenta importante para o diagnóstico de neurosífilis, mesmo nos pacientes que apresentam VDRL sérico negativo.

Unitermos. Sífilis, Sistema Nervoso Central, Neurosífilis.

Citação. Moro A, Bresciani AP, Oliveira MV, Albino PHC, Bertotti MM, Bruscato AM, Queiroz LP, Mattosinho Filho P. Neurosífilis e Variantes Clínicas.

Study Performed at Neurology Department, Governador Celso Ramos Hospital, Florianópolis SC, Brazil.

1. Resident of Neurology, Florianópolis-SC, Brazil.
2. Resident of Neurosurgery, Florianópolis-SC, Brazil.
3. MD, Neurologist, Neurology Residency Program Preceptor, Florianópolis-SC, Brazil.
4. MD, PhD, Neurologist, Neurology Residency Program Preceptor, Head of the Neurology Residency, Florianópolis-SC, Brazil.
5. MD, Neurologist, Neurology Residency Program Preceptor, Head of the Neurology Department, Florianópolis-SC, Brazil.

Endereço para correspondência:

Luiz Paulo Queiroz
Rua Irmã Benwarda, 297, Centro
Centro de Estudos Danilo Freire Duarte
CEP 88015-270, Florianópolis-SC, Brasil.
E-mail: lpqueiroz@floripa.com.br

Relato de Caso
Recebido em: 07/10/10
Aceito em: 20/04/12
Conflito de interesses: não

INTRODUCTION

Syphilis is a chronic infectious disease caused by the bacterium *Treponema pallidum*, early affecting the central nervous system (CNS)^{1,2}. About 30% of untreated individuals develop the late CNS disease³. The incidence of neurosyphilis has declined dramatically in the decades following World War II with the advent of penicillin⁴. However, in recent years, the number of reported cases is increasing, both in immunosufficient individuals and in the immunocompromised^{5,6}.

Establishing the incidence of neurosyphilis associated with infection by Human Immunodeficiency Virus (HIV) is difficult, but it's known the presence of syphilis infection is a risk factor for HIV infection due to disruption of the mucocutaneous barrier in genital lesions, as well as the immunosuppression associated with acquired immunodeficiency syndrome (AIDS) speeds the course of this disease⁷. Moreover, "neurorecurrence", which is the development of symptomatic infection of the CNS after standard treatment for early syphilis^{2,3,6}, has been reported. Early development of tertiary manifestations has been suggested⁸. The prevalence of neurosyphilis in HIV-infected patients with late latency syphilis is estimated in 9.1% to 23.5%⁹.

Each one of the neurological manifestations of syphilis is consequence of insidious chronic meningeal inflammation. There is an inflammatory response in cerebrospinal fluid (CSF) in at least one third of patients with untreated asymptomatic syphilis, with reports reaching 70% in some articles¹. Exceptionally, this inflammatory process is intensified in its acute form, causing cranial nerve palsies, seizures, apoplectic phenomena and symptoms of increased intracranial pressure. This meningeal inflammation can persist without producing symptoms and, after a period of years, can lead to parenchymal damage².

The clinical findings are extremely variable and can be divided into early and late neurosyphilis¹⁰. Early forms are meningitis and meningovascular syphilis, acute and subacute myelopathy, cranial nerve abnormalities and ocular damage, while vascular lesions followed later by general paresis, tabes dorsalis, optic atrophy, meningomyelitis, dementia and sensory ataxia^{5,10} can appear in the late diseases. Since they have the common origin in a

meningeal inflammatory process, there is often a combination of two or more forms⁵.

Considering that neurosyphilis became less frequent and often it's not considered in the diagnosis of the patients, the aim of this study is to describe four cases of this disease, treated at the Hospital Governador Celso Ramos (HGCR), with their respective clinical manifestations.

METHOD

Three patients, previously undiagnosed, were evaluated by the Neurology Department, at the HGCR, in Florianópolis/SC, Brazil, from January 2008 to March 2010. All patients underwent laboratory tests, including CSF analysis after lumbar puncture, and imaging investigation, including computed tomography (CT) and/or magnetic resonance imaging (MRI) of the brain.

This study was approved by the ethics committee of the hospital (protocol number 0012/2010) and patients signed an informed consent agreement, authorizing the publication of the information regarding the case history.

Cases Report

Case 1: male, 61 years, unmarried, complaining of a progressive decrease of visual acuity on the left eye, reporting "white spots", viewing only part of the visual field, fifteen days before admission. Eight years ago, he had a similar episode in the right eye, but not undergoing treatment at that time, evolving with partial loss of the vision. He denied previous infections, including HIV, confirmed by negative anti-HIV test, and he also did not note any genital lesion in the past. The fundus oculi examination showed right optic disc pallor and papilledema in the left. Venereal Disease Research Laboratory (VDRL) in blood was 1/128; VDRL in CSF 1/1, considered reactive, and the Fluorescent Treponemal Antibody Absorption (FTA-ABS) with twice the threshold value. The rest of CSF investigation was unremarkable, and included oligoclonal bands and intrathecal immunoglobulin G (IgG) production. There were no signs of lumbar puncture accidents. Anti-nuclear factor, rheumatoid factor and serum antibodies against aquaporin 4 were negative. MRI of the brain showed right optic nerve atrophy and thickening of the left optic nerve (Figure 1).

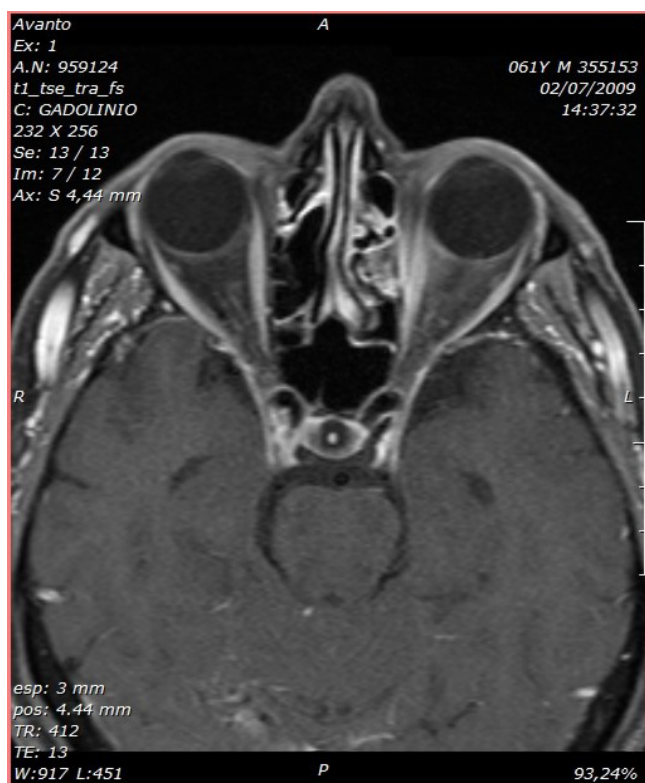


Figure 1. MRI of the brain showing asymmetry of optic nerves with signs of thickening of the left optic nerve.

Case 2: male, 32 years, married, with a history of an ischemic stroke six months before, in the territory of the right middle cerebral artery. He had left central facial palsy, left hemiparesis with Babinski sign on the left. He didn't report genital lesions consistent with syphilis in the past. Screening for the etiology of ischemic stroke in young adults did not show either any evidence of thrombophilia, or any lesions on brain arteriography, contrast-enhanced transesophageal echocardiography or in carotid Doppler. Anti-HIV test was negative; VDRL was 1/128 and FTA-ABS was detected in blood. The CSF analysis resulted in 14 cells/mm³ (100% lymphomononuclear), high protein concentration (62 mg/dL), non-reactive VDRL and a positive FTA-ABS. CT scan showed cortical and subcortical volume reduction with right fronto-temporal predominance and mild hypoattenuation of the right frontoparietal subcortical white matter.

Case 3: woman, 57 years, divorced, without previous history of headache, came to the Neurology Department with a left-sided persistent and progressive headache, especially retro-orbital, which began eight days before, associated with conjunctival hemorrhage, photo

and phonophobia, which evolved with decreased visual acuity of the left eye. On physical examination, there was left ptosis, right-sided hypoesthesia, without motor deficits, and postural tremor in the right arm. There was no history of sexually transmitted disease in the past. Initial CSF examination showed 10 cells/mm³, raised protein concentration and nonreactive VDRL. VDRL in blood was positive, with a titer of 1/64. In a new CSF analysis, a reactive FTA-ABS concluded the diagnosis as neurosyphilis. Brain CT revealed meningeal enhancement. Treatment with crystalline penicillin (24 million IU per day, during fourteen days) resulted in progressive improvement. All patients were treated with crystalline penicillin 4 million IU intravenously 6 times a day for two weeks. Subsequently, CSF analysis showed resolution of the infection in all cases.

DISCUSSION

There is no ideal test to establish or exclude the diagnosis of neurosyphilis. The CSF is a sensitive indicator of active neurosyphilitic infection. A chronic inflammatory CSF accompanies each of the clinical syndromes of neurosyphilis⁵. The CSF abnormalities consist of (a) pleocytosis greater than 100 cells per mm³, sometimes even larger, with lymphocyte predominance; (b) elevation of total protein (40-200 mg/dl); (c) increase of gamma globulin (IgG), usually with the presence of oligoclonal bands; and (d) positive serologic tests. The glucose content is usually normal^{5,10}.

Nevertheless, in the cases reported, the abnormalities of CSF were varied. In the first case, the patient had no chronic inflammatory response of the LCR, despite the visual loss. In the second, there was a predominance of mononuclear cells in CSF. There was not a pleocytosis greater than 100 cells/mm³ in any case, which is consistent with the literature, since the increase in cellularity and protein are present in only 10% of the patients³.

The serological diagnosis of syphilis depends on the presence of one of two types of antibodies - non-specific or non-treponemal and treponemal ones. The most common test is the VDRL. This test, if reactive in CSF makes the diagnosis of neurosyphilis⁶. Test reagents in serum are specific but lack sensitivity, and they are negative in a significant proportion of patients with late syphilis.

CSF VDRL is positive in no more than 50% of patients with symptomatic infection of SNC³. These patients and those with suspected false-positive test requires the testing of antibodies that are specifically directed against treponemal antigens. (FTA-ABS) is most common in use and more appropriate for most situations⁵, with higher sensitivity and specificity⁴. In case 3, the CSF VDRL was negative; however, as the serum VDRL was positive, there was the suspicion of a false negative, which prompted the FTA-ABS in the CSF, which was reactive. False-negatives may occur in up to 32% of patients in cases of early primary disease, latent or late syphilis, and also in patients co-infected with HIV⁴. False positive VDRL and FTA-ABS in the CFS also may occur, but it is rare¹¹.

In the pre-antibiotic era, ocular complications occurred in 3% of patients with secondary syphilis. This percentage is higher in patients co-infected with HIV, up to 10% in some series^{10,12}. Ocular involvement may be silent or present as anterior uveitis, choroiditis, interstitial keratitis, retinal vasculitis, retinitis, optic neuritis or esclerite⁴. One manifestation is the optic atrophy, which causes progressive blindness, starting in one eye and involving the other. The usual finding is a constriction of visual fields, but scotomata can occur in several cases. The prognosis is worse if the vision in both eyes is greatly compromised. The pathological findings consist of optical meningitis, with subpial gliosis and fibrosis replacing the fibers of the optic nerve destroyed⁵. The first case describes this form, characterized by progressive loss of visual acuity in one eye began with an interval of eight years until the onset of other. A diagnosis of multiple sclerosis was considered, but the brain MRI did not show any typical demyelinating lesion. Devic disease, collagen vascular disease and vasculitis were also considered. The patient was underwent on pulse therapy with methylprednisolone 1 g/day for 3 days followed by oral corticosteroid therapy associated with the use of crystalline penicillin 24 million IU/day for 14 days, showing partial regression of left visual symptoms, but remaining low acuity in the right, as a sequel of the disease untreated.

Syphilis meningovascular corresponds to the clinical form in 2-10% of patients with CNS involvement. It usually occurs between 6 and 7 years after the original infection and may present in a great variability, described

from six months to 10 years^{5,13-15}. Clinically, syphilis meningovascular can manifest itself by acute stroke, particularly ischemic or, more commonly, as sub acute illness, with a prodrome of weeks or months. Heubner's arteritis is the most common vasculitis in syphilis meningovascular reaching arteries of medium and large caliber, with proliferation of fibro-elastic intima, narrowing of the middle and associated fibrosis with inflammatory changes in the adventitia leading to stenosis and ectasia of the stricken vessel⁸. The second case refers to a young patient with ischemia in the area of the middle cerebral artery whose etiological investigation proved neurosyphilis. The middle cerebral artery branches are the most often affected, but any vascular territory in the brain or in the spinal cord can be stricken^{5,7,8,15}. The diagnosis is established by lying inflammatory CSF with positive serological results for syphilis. Angiography is not necessary to reach the diagnosis. The ischemic areas shown by CT or MRI in combination with typical CSF findings suggest the diagnosis.

Meningeal neurosyphilis occurs in 25% of all cases, appearing about two years after primary infection with *Treponema pallidum*. The most frequent symptoms and signs are headache, neck stiffness, cranial nerve palsies, seizures and mental confusion. The CSF shows cloudy appearance and a high opening pressure. There is intense pleocytosis (more than 200 cells/mm³), normal or decreased glucose levels, increased protein concentration (above 40 mg/dl) and intrathecal synthesis of immunoglobulin G (IgG) (IgG index greater than 0.7)¹⁶. This form of infection may characterize the third case described.

Neuroradiological exams are not specific in the diagnosis of neurosyphilis, and there are often no changes on magnetic resonance imaging or CT scans, which do not exclude the diagnostic⁴. In cases of tabes dorsalis, the images of MRI showed atrophy typically associated with hyperintense T2 signal and contrast uptake of the posterior spinal cord and dorsal nerve roots. Approximately one third of CT scans are negative, and another third just shows brain atrophy. Small foci of ischemia or infarction secondary to vasculitis can be identified by CT and MRI - as noted in case 2. Multiple hyperintense foci in T2 are seen involving both the gray matter as the white subcortical location, and involvement of the basal ganglia. Meningeal uptake of contrast can also be shown¹⁶.

Treatment with antibiotics is the ultimate goal of normalization of CSF¹⁷. The treatment prevents the progression of the disease, and even, some improvement is frequently reported in the literature^{18,19}. However, significant improvement or even complete reversal of symptoms is somewhat not expected, due to irreversible destruction of neurons by *Treponema pallidum*^{17,20}. Like all clinical types of neurosyphilis are associated with an inflammatory response in CSF, type and number of cells is the best monitor the effectiveness of treatment. There are no reports of clinical relapses after the CSF is normal. Penicillin is the agent of choice³, and yet there was no resistance to antimicrobial agents. Several schemes are suggested as a treatment, ranging from 12 to 24 million units/day. The Center for Disease Control, recommends 18 million to 24 million units/day for 10 days, although we ignore the optimal duration of treatment^{17,21}. At the department of Neurology of HGCR, the option is the application of 24 million units/day for 14 days.

The treatment of neurosyphilis in patients co-infected with HIV is identical to that in patients without retrovirus²¹. The follow-up, however, is more aggressive. The control of HIV-induced immunosuppression is an important target of therapy in order to reduce long term morbidity of patients' co-infection²².

The full normalization of the CSF is unusual in the usual course of two to three weeks of intravenous treatment, but its improvement occurs gradually to normalize in the course of weeks to months. Evidence that the treatment was proper consists of a normal cellularity and protein content decreased after six months⁵. The title of VDRL should decrease by four times, usually within the first 6-12 months. All patients should be reviewed every 3 or 6 months and liquor reassessed every six months during the next two years⁴.

CONCLUSION

The diagnosis of syphilis is not difficult when the patient shows signs and symptoms of the disease. However, the CSF examination is the only way to make the diagnosis of neurosyphilis, which may be a confounding factor when it is found normal cellularity or nonreactive VDRL. Studies searching for new diagnostic tools, such as the dosage in the CSF of B lymphocyte chemoattractant chemokine ligand 13 (CXCL13), but its applicability is not yet defined^{6,23}, since this chemokine is also found in several other diseases³.

REFERENCES

- Marra CM, Maxwell CL, Smith SL, Lukehart SA, Rompalo AM, Eaton M, et al. Cerebrospinal Fluid Abnormalities in Patients with Syphilis: Association with Clinical and Laboratory Features. *JID* 2004;189:369-76. <http://dx.doi.org/10.1086/381227>
- Libois AS, Wit SP, Poll BND, Garcia F, Florence E, Del Rio A, et al. HIV and Syphilis: When to Perform a Lumbar Puncture. *Sexually Transmitted Diseases* 2007;34(3):141-44. <http://dx.doi.org/10.1097/01.olq.0000230481.28936.e5>
- Sparling PF. Diagnosis of Neurosyphilis: New Tools. *Sexually Transmitted Diseases* 2010;37(5):288-9.
- Smith GT, Goldmeier D, Migdal C. Neurosyphilis with optic neuritis: an update. *Postgrad Med J* 2006;82:36-9. <http://dx.doi.org/10.1136/pgmj.2004.020875>
- Adams R, Victor M. Principles of neurology. 8 Ed. New York: McGraw-Hill; 2005, p.614-8.
- Marra CM, Tantaló LC, Sahi SK, Maxwell CL, Lukehart SA. CXCL13 as a Cerebrospinal Fluid Marker for Neurosyphilis in HIV-Infected Patients With Syphilis. *Sexually Transmitted Diseases* 2010;37(5):283-7.
- Katz DA, Berger JR, Duncam RC. Neurosyphilis: a comparative study of the effects of infection with human immunodeficiency virus. *Arch Neurol* 1993;50:243-249. <http://dx.doi.org/10.1001/archneur.1993.00540030009006>
- Powell AL, Coyne AC, Jen L. A retrospective study of syphilis seropositivity in a cohort of demented patients. *Alzheimer Dis Assoc Disord* 1993;7:33-38. <http://dx.doi.org/10.1097/00002093-199307010-00004>
- Holtom PD, Robert AL, Leal ME, Leedom JM. Prevalence of neurosyphilis in human immunodeficiency virus-infected patients with latent syphilis. *Am J Med* 1992;93:9-12. [http://dx.doi.org/10.1016/0002-9343\(92\)90673-Y](http://dx.doi.org/10.1016/0002-9343(92)90673-Y)
- Zetola NM, Engelman J, Jensen TP, Klausner JD. Syphilis in the United States: An Update for Clinicians With an Emphasis on HIV Coinfection. *Mayo Clin Proc* 2007;82(9):1091-1102. <http://dx.doi.org/10.4065/82.9.1091>
- Madiedo G, Ho KC, Walsh P. False-Positive VDRL and FTA in Cerebrospinal Fluid. *JAMA* 1980;244(7):688-689. <http://dx.doi.org/10.1001/jama.1980.03310070038026>
- Balba GP, Kumar PN, James AN, Malani A, Palestine AG, Welch JN, et al. Ocular syphilis in HIV-positive patients receiving highly active antiretroviral therapy. *Am J Med* 2006;119(5):448.e21-e25.
- Holland BA, Perrett LV, Mills CM. Meningovascular syphilis: CT and MR findings. *Radiology* 1986;158:439-442.
- Harriman DGF. Bacterial infections of nervous system. In Blackwood W, Dorselis JAN. (eds). *Greenfield's neuropathology*. London: Edward Arnold; 1976, p.253-256.
- Lambrech F, Sá DS, Koerbel A, Tamanini A, Machareth SL, Scola RH, et al. Oclusão Bilateral das Artérias Carótidas Internas, Sífilis Meningovascular e Sida. *Relato de Caso. Arq Neuropsiquiatr* 1999;57(2-A):311-316. <http://dx.doi.org/10.1590/S0004-282X1999000200025>

- 16.Sohler MP. Diagnóstico de Neuroinfecção. Rio de Janeiro: Editora Rubio; 2008 p.132.
- 17.Hook EW. Syphilis. In Scheld WM, Whitley RJ, Durak DT. Infections of central nervous system. 2Ed. Philadelphia: Lippicott Raven; 1997, p.669-684.
- 18.Uribe CS, Garcia FA. Neurosífilis y efecto prozona. Rev Neurol 1998;27:970-972.
- 19.Himmelman A, Schaffner A, Greminger P. Dementielle Enticwicklung. Schw Rundsch Med Prax 1993; 82:1205-1208.
- 20.Bschor T, Nurbach-Roos B, Albrecht J. Organish Genese einer maniformen Psychose: ein Fallbeispiel von progressiver Paralyse. Nervenarzt 1995;66:54-56.
- 21.Workowski KA, Berman SM. Centers for Disease Control and Prevention. Sexually transmitted diseases treatment guidelines, 2006. Morbidity & Mortality Weekly Report 2006;55(RR-11):1-94.
- 22.Ghanem KG, Moore RD, Rompalo AM, Erbeling EJ, Zenilman JM, Gebo KA. Neurosyphilis in a clinical cohort of HIV-1-infected patients. AIDS. 2008;22(10):1145-51.
<http://dx.doi.org/10.1097/QAD.0b013e32830184df>
- 23.Rupprecht TA, Kirschning CJ, Popp B, Kastenbauer S, Fingerle V, Pfister H, et al. Borrelia garinii induces CXCL13 production in human monocytes through Tolllike receptor 2. Infect Immun 2007;75:4351-56.
<http://dx.doi.org/10.1128/IAI.01642-06>