

# Clinical evolution of late-onset Pompe disease: a case report

*Evolução clínica da Doença de Pompe de início tardio: relato de caso*

*Evolución clínica de la Enfermedad de Pompe de aparición tardía: reporte de caso*

Leonardo Cortez Guerra<sup>1</sup>, Bruna Orbite Garcia<sup>2</sup>, Maria da Penha Ananias Morita<sup>3</sup>, Fernanda Aparecida Novelli Sanfelice<sup>4</sup>

1. Medical student, Centro Universitário Padre Albino (UNIFIPA). Catanduva-SP, Brazil.

2. Medical student, Faculdade Ceres (FACERES). São José do Rio Preto-SP, Brazil.

3. Neurologist, Master, Faculdade de Medicina de São José do Rio Preto (FAMERP). São José do Rio Preto-SP, Brazil.

4. Nurse, Master, Faculdade Ceres (FACERES). São José do Rio Preto-SP, Brazil.

---

## Resumo

**Introdução.** A doença de Pompe é uma miopatia metabólica hereditária devido à deposição de glicogênio lisossomal na ausência ou redução da atividade da enzima maltase ácida. A prevalência mundial da doença varia de 1:40.000 a 1:200.000 e afeta crianças e adultos.

**Objetivo.** Este trabalho tem como objetivo relatar o caso de um paciente diagnosticado com a forma tardia da doença de Pompe. **Relato do Caso.** Paciente do sexo feminino, 44 anos, iniciou os sintomas da doença de Pompe aos 14 anos, apresentando dificuldade de deambulação e quedas frequentes. A doença foi diagnosticada três anos depois. Aos 44 anos e em uso de terapia de reposição enzimática há 12 anos, o quadro clínico evoluiu para tetraplegia e comprometimento da musculatura respiratória e orofacial. **Conclusão.** Apesar do uso da TRE e o cuidado realizado por uma equipe multidisciplinar, a paciente evoluiu com um desfecho clínico desfavorável. Então, o diagnóstico precoce, o nível de atividade enzimática e a resposta ao tratamento com reposição enzimática são essenciais para o prognóstico da doença.

**Unitermos.** Doença de Depósito de Glicogênio Tipo II; Doença de Pompe; Terapia de Reposição Enzimática; Relato de caso; Assistência médica

---

## Abstract

**Introduction.** Pompe disease is an inherited metabolic myopathy due to lysosomal glycogen deposition in the absence or reduction of acid maltase enzyme activity. The worldwide prevalence of the disease ranges from 1:40,000 to 1:200,000 and it affects children and adults. **Objective.** This study aims to report the case of a patient diagnosed with the late form of Pompe disease. **Case Report.** A 44-year-old female patient had the onset of symptoms of Pompe disease at the age of 14, presenting difficulty in walking and frequent falls. The disease was diagnosed three years later. At the age of 44 and after using enzyme therapy replacement (TER) for 12 years, the clinical condition evolved into quadriplegia and involvement of the respiratory and orofacial muscles, despite the use of enzyme replacement therapy for 12 years. **Conclusion.** Despite the use of ERT and the care provided by a multidisciplinary team, the patient evolved with an unfavorable clinical outcome. Therefore, early diagnosis, level of enzyme activity, and response to treatment with enzyme replacement are essential for the disease prognosis.

**Keywords.** Glycogen Storage Disease Type II; Pompe Disease; Enzyme Replacement Therapy; Case Report; Health Care

---

## Resumen

**Introducción.** La enfermedad de Pompe es una miopatía metabólica hereditaria debida al depósito de glucógeno lisosomal en ausencia o reducción de la actividad de la enzima maltasa ácida. La prevalencia mundial de la enfermedad varía de 1:40.000 a 1:200.000 y afecta a niños y adultos. **Objetivo.** Este estudio tiene como objetivo reportar el caso de un paciente diagnosticado con la forma tardía de la enfermedad de Pompe. **Caso Clínico.** Paciente femenina de 44 años de edad con inicio de síntomas de enfermedad de Pompe a los 14 años, presentando dificultad para caminar y caídas frecuentes. La enfermedad fue diagnosticada tres años después. A la edad de 44 años y Después de utilizar terapia de reemplazo enzimático (TER) durante 12 años, el cuadro clínico evolucionó a tetraplejía y compromiso de los músculos respiratorios y orofaciales. **Conclusión.** A pesar del uso de TER y la atención brindada por un equipo multidisciplinario, el paciente evoluciono con una enlución clínica desfavorable. Por lo tanto, el diagnóstico precoz, el nivel de actividad enzimática y la respuesta al tratamiento con reposición enzimática son fundamentales para el pronóstico de la enfermedad.

**Palabras clave.** Enfermedad por almacenamiento de glucógeno tipo II; Enfermedad de Pompe; Terapia de Reemplazo Enzimático; Informe de caso; Aceptación de la Atención de Salud

---

Research developed at Faculdade CERES (FACERES). São José do Rio Preto-SP, Brazil.

Conflict of interest: no

Received in: 07/06/2022

Accept in: 09/14/2022

Corresponding address: Fernanda AN Sanfelice. Av. Anísio Haddad 6751. Jardim Francisco Fernandes. São José do Rio Preto-SP, Brazil. Zip code: 15090-305. Telephone: +55 (17) 3201-8200. Email: [fersanfe@hotmail.com](mailto:fersanfe@hotmail.com)

---

## INTRODUCTION

Pompe disease (PD), also known as acid maltase deficiency, is an autosomal recessive lysosomal storage disease that leads to the absence or reduction in the activity of the lysosomal acid alpha-glucosidase (GAA)<sup>1</sup>. Its worldwide prevalence is around 1:40,000 to 1:200,000 and varies in different parts of the world<sup>2</sup>.

Infantile-onset Pompe disease (IOPD) is the most frequent and severe form, the patients usually present symptoms at the end of the first year of life<sup>3</sup>. IOPD is clinically characterized by severe early-onset neonatal hypotonia, cardiomyopathy, hepatomegaly, macroglossia, and respiratory failure, these patients usually have less than 1% of GAA enzymatic activity<sup>1</sup>.

In Late-onset Pompe disease (LOPD), the disease manifests after the first year of life, with the onset of symptoms being more common in the third decade of life<sup>4,5</sup>. In this group, the disease presents with proximal weakness, which makes a differential diagnosis especially with the autosomal recessive limb-girdle muscular dystrophies<sup>6</sup>. Some particularities help to differentiate them, for example, early respiratory muscle involvement, facial and axial muscle weakness are more common in Pompe disease<sup>6</sup>. Cardiomyopathy does not occur, as observed in IOPD<sup>1</sup>. Also, the activity of the GAA enzyme is low, ranging from 1 to 40%, and the activity level is usually related to the precocity and severity of symptoms in the late form of the disease<sup>6</sup>.

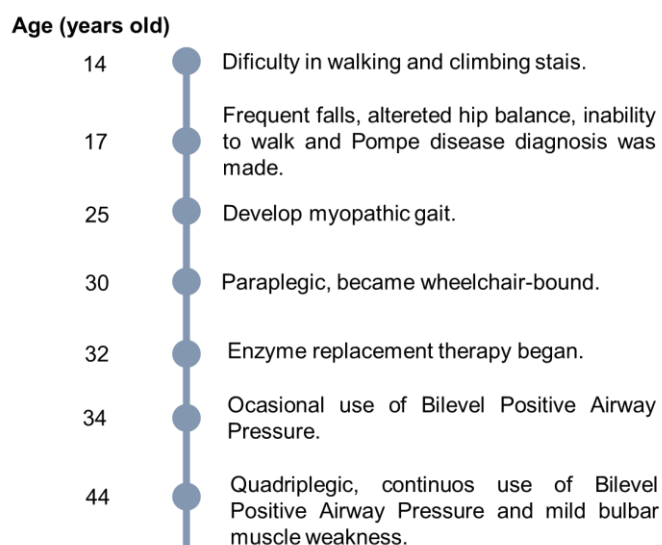
Enzyme Replacement Therapy (ERT) with Alpha-glucosidase, the synthetic GAA enzyme produced in a laboratory by biotechnology that replaces the natural enzyme, is the first-line therapy for both clinical forms<sup>1</sup>.

## **CASE REPORT**

A 44-year-old female patient, white, single, with negative family history and parental consanguinity. The onset of symptoms began in 1989, when she was 14, presenting difficulty in walking and inability to run. It evolved with progressive worsening with frequent falls and difficulty in getting up off the floor, altered hip balance during gait, and difficulty in climbing stairs. In 1992, she was evaluated at a specialized service in neuromuscular

diseases, where serum CK (creatine phosphokinase enzyme) was measured and a muscle biopsy with histochemical study and an electroneuromyography were performed. With these tests, especially muscle biopsy, the diagnosis of Glycogenosis type II was suspected, that is, PAS (Periodic acid-Schiff) positive vacuolar myopathy due to lysosomal glycogen deposition. Laboratory tests revealed: hyperCKemia (533U/l; seven times the reference value at the time), elevated aspartate aminotransferase (78U/l) and alanine aminotransferase (88U/l) levels, and a raised serum aldolase level (8.4U/l, creatinine (0.4mg/dl). Also, the patient had normal glucose and urea serum levels. Figure 1 shows a timeline with the main clinical characteristics. At that time, without the availability of specific treatment with ERT, treatment with motor and respiratory physiotherapy and clinical follow-up were recommended.

Figure 1. Timeline containing the main clinical events of the patient.



Eleven years after the onset of symptoms, the patient reported significant loss of muscle strength in limbs, but denied ocular, bulbar complaints, and respiratory difficulty. At that time, she had a gait with intense weakness in the hip muscles and hyperlordosis, with feet dropped bilaterally (myopathic gait). She could not walk on tiptoe or heels and crouch to the ground.

In 2003, after being hospitalized for treatment of pneumonia, she became partially dependent on the nocturnal use of BiPAP (Bilevel Positive Airway Pressure). In 2005, at the age of 30, she lost her ability to walk and became wheelchair-bound. Due to new treatment perspectives available she was contacted again by a specialized service in muscle diseases in 2008 and a muscle biopsy was repeated with a histochemical study as well as a collection of DBS (Dried Blood Spot), which confirmed GAA deficiency with a percentage of enzyme inhibition of 89.77% and the ratio between neutral alpha-glucosidase and alpha-glucosidase inhibited by acarbose (NaG/AaGIA) of 71.69. Spirometry also revealed a severe restrictive pattern with forced vital capacity (FVC) of 16.6% and forced expiratory volume in 1 second (VEF1) of 19.6%. Thus, the treatment with Alpha-alglucosidase 20 mg/kg every 15 days for a life-long treatment was initiated, and it has been used since then.

After 1 year the patient started with the ERT with alpha-alglucosidase, the patient presented stabilization of respiratory function and was referred to the need to use

BIPAP only in cases of pulmonary infectious complications. The patient showed prolonged periods of complete independence; however, despite the treatment with ERT, motor and respiratory physiotherapy, adequate nutrition, and speech therapy, the patient evolved with progressive worsening and in her last evaluation, in 2021, she was dependent on the use of continuous BIPAP due chronic ventilatory failure associated with the use of accessory muscle, quadriplegic (frustrated movements of some distal muscles in the limbs), global areflexia, hypotonia, generalized muscle atrophy, marked facial weakness and mild bulbar muscle weakness (dysphagia, rare episodes of choking). She did not present hepatomegaly, ptosis, macroglossia, and urinary incontinence. Laboratory tests show: elevated CK level (103U/l), decreased creatinine serum level (0.45mg/dl) and normal serum levels of aspartate aminotransferase, alanine aminotransferase, and glucose. There was no cardiac involvement confirmed by an electrocardiogram and echocardiogram. Also, due to the involvement of the paravertebral musculature and for being bedridden the patient developed scoliosis. Currently, due to her condition, she needs constant help to perform basic life activities, such as bathing, personal hygiene, eating, transferring, and dressing.

This study was approved by the Ethics Committee of Faculdade CERES (approval number: 4.798.368; CAAE: 46833521.9.0000.8083).

## **DISCUSSION**

Pompe disease is an underdiagnosed, rare, and serious genetic disease, especially in late-onset cases whose initial symptoms may go unnoticed for a long period or be confused with other clinical diseases and, especially with other myopathies<sup>5,7</sup>. Early diagnosis has important implications for the evolution of the disease and the patient's quality of life since it is a currently treatable disease by enzyme replacement with proven efficacy and better results if the treatment starts early too<sup>8</sup>. Fortunately, nowadays it is easier to obtain the necessary laboratory tests; however, the greatest difficulty lies in the availability of specialized services in neuromuscular diseases, which are still scarce in Brazil. Also, there were approximately 106 PD patients under ERT in 2018 in Brazil, so Brazil lacks epidemiological data on PD<sup>9</sup>.

This case report is about a patient who presented the first symptoms of PD at the age of 14, a late-onset PD that was diagnosed about 3 years after the initial symptoms. Unfortunately, the diagnosis was confirmed and there was no specific treatment with ERT at that time, so the patient only started it at the age of 33, in the advanced stage of the disease, 16 years after the initial symptoms. The DBS showed that the patient had approximately 10% GAA enzyme activity, a considerable reduction for patients with the late form, which justifies the earlier onset of symptoms and severity among patients with LOPD<sup>10</sup>. Such findings are consistent with its severe course and probably with the

very inadequate response to treatment with ERT. In addition, PD patients (especially in IOPD) can develop anti-drug antibodies against ETR (anti-thGAA) which affect the efficacy and safety of the drug, however, the relationship between LOPD and anti-thGAA, especially regarding clinical outcomes, is unclear<sup>11</sup>.

Studies show that enzyme replacement adequately prevents the accumulation of glycogen in tissues, but it does not reverse tissue damage that has already been established<sup>8</sup>. Therefore, the diagnosis in the early stages of the disease and rapid initiation of ERT with alpha-glucosidase are essential for a less bleak prognosis. ERT showed stabilization of lung function and there was no improvement in limb muscle strength<sup>5,8</sup>. Other reports also show an initial trend towards improvement and/or stabilization of respiratory function and persistence of worsening in appendicular muscle strength<sup>2,11</sup>. The patient showed that, even with treatment, there was a progression of the disease, mainly in muscle function. To date, no extramuscular involvement by glycogen deposition has been found in the patient. It is possible that ERT was effective in maintaining and preventing injury to non-compromised organs at the beginning of the treatment, which could be considered one more reason to invest in early diagnosis and treatment. However, the clinical outcomes of LOPD patients are heterogeneous<sup>11</sup>. In addition, short-time ERT interruption was associated with clinical deterioration<sup>12</sup>.



## CONCLUSION

Pompe disease is a rare, severe and progressive genetic disease, which has an effective treatment but with heterogeneous outcomes, especially considering the clinical stage at the beginning of the treatment. It is concluded that the data presented are similar to those of other authors that the diagnosis and initiation of specific treatment are fundamental for the prognosis and that is reported in the case. Although the diagnosis was rapid, the lack of specific treatment at that time, which was instituted late with the patient being clinically very compromised, was crucial for the poor outcome. Nowadays, a similar case has greater possibilities of having better results and provide a better quality of life to the patients.

## REREFÊNCIAS

- 1.Kohler L, Puertollano R, Raben N. Pompe Disease: From Basic Science to Therapy. *Neurotherapeutics* 2018;15:928-42. <https://doi.org/10.1007/s13311-018-0655-y>
- 2.Schoser B, Stewart A, Kanters S, Hamed A, Jansen J, Chan K, *et al.* Survival and long-term outcomes in late-onset Pompe disease following alglucosidase alfa treatment: a systematic review and meta-analysis. *J Neurol* 2017;264:621-30. <https://doi.org/10.1007/s00415-016-8219-8>
- 3.Disease AWGoMoP, Kishnani PS, Steiner RD, Bali D, Berger K, Byrne BJ, *et al.* Pompe disease diagnosis and management guideline. *Genet Med* 2006;8:267-88. <https://doi.org/10.1097/01.gim.0000218152.87434.f3>
- 4.Loscher WN, Huemer M, Stulnig TM, Simschitz P, Iglseder S, Eggers C, *et al.* Pompe disease in Austria: clinical, genetic and epidemiological aspects. *J Neurol* 2018;265:159-64. <https://doi.org/10.1007/s00415-017-8686-6>
- 5.Vanherpe P, Fieuws S, D'Hondt A, Bleyenheuft C, Demaerel P, De Bleecker J, *et al.* Late-onset Pompe disease (LOPD) in Belgium: clinical characteristics and outcome measures. *Orphanet J Rare Dis* 2020;15:83. <https://doi.org/10.1186/s13023-020-01353-4>
- 6.Llerena Junior JC, Nascimento OJ, Oliveira AS, Dourado Junior ME, Marrone CD, Siqueira HH, *et al.* Guidelines for the diagnosis,

treatment and clinical monitoring of patients with juvenile and adult Pompe disease. *Arq Neuropsiquiatr* 2016;74:166-76.

<https://doi.org/10.1590/0004-282X20150194>

7. Musumeci O, la Marca G, Spada M, Mondello S, Danesino C, Comi GP, *et al.* LOPED study: looking for an early diagnosis in a late-onset Pompe disease high-risk population. *J Neurol Neurosurg Psychiatry* 2016;87:5-11. <https://doi.org/10.1136/jnnp-2014-310164>

8. van der Ploeg AT, Clemens PR, Corzo D, Escolar DM, Florence J, Groeneveld GJ, *et al.* A randomized study of alglucosidase alfa in late-onset Pompe's disease. *N Engl J Med* 2010;362:1396-406.

<https://doi.org/10.1056/NEJMoa0909859>

9. Brasil. Ministério da Saúde. Secretaria de Ciência, Tecnologia, Inovação e Insumos Estratégicos em Saúde; Departamento de Gestão e Incorporação de Tecnologias e Inovação em Saúde. Protocolo Clínico e Diretrizes Terapêuticas da doença de pompe. Brasília (DF); 2021. (Access: June 15, 2022). Available in:

[http://conitec.gov.br/images/Protocolos/Publicacoes\\_MS/PCDT\\_Doenca\\_de\\_Pompe\\_Final\\_ISBN.pdf](http://conitec.gov.br/images/Protocolos/Publicacoes_MS/PCDT_Doenca_de_Pompe_Final_ISBN.pdf)

10. Musumeci O, Toscano A. Diagnostic tools in late onset Pompe disease (LOPD). *Ann Transl Med* 2019;7:286.

<https://doi.org/10.21037/atm.2019.06.60>

11. Harlaar L, Hogrel JY, Perniconi B, Kruijshaar ME, Rizopoulos D, Taouagh N, *et al.* Large variation in effects during 10 years of enzyme therapy in adults with Pompe disease. *Neurology* 2019;93:e1756-67.

<https://doi.org/10.1212/WNL.0000000000008441>

12. Wenninger S, Gutschmidt K, Wirner C, Einvag K, Montagnese F, Schoser B. The impact of interrupting enzyme replacement therapy in late-onset Pompe disease. *J Neurol* 2021;268:2943-50.

<https://doi.org/10.1007/s00415-021-10475-z>